

TOXOCARIASIS AND INTESTINAL VOLVULUS IN AN ISLAND FLYING FOX (*PTEROPUS HYPOMELANUS*)

Darryl J. Heard, B.Sc., B.V.M.S., Ph.D., Michael Garner, D.V.M., and Ellis Greiner, Ph.D.

Abstract: A 2-mo-old island flying fox (*Pteropus hypomelanus*) died from toxemia secondary to a small intestinal volvulus associated with severe toxocariasis. The stomach, duodenum, and anterior half of the jejunum were markedly distended by 20 nematodes (12–14 cm in length) identified as *Toxocara pteropodis*.

Key words: *Toxocara pteropodis*, intestinal volvulus, island flying fox, *Pteropus hypomelanus*.

INTRODUCTION

The nematode parasite, *Toxocara pteropodis*, has been isolated from the four Australian flying fox species (*Pteropus poliocephalus*, *P. alecto*, *P. conspicillatus*, and *P. scapulatus*) as well as *P. geddiei* from Vanuatu.^{1,5} Its life cycle involves maturation in the intestine of suckling pups which pass eggs in their feces beginning at about 2 mo of age.^{4,6} The eggs are ingested by adult bats, and the larvae hatch and migrate to the liver via the portal circulation.⁶ In periparturient and lactating females some of these larvae become active, migrate to the mammary glands, and are passed in the milk to the pups to complete the cycle. The adult worms are shed spontaneously by the pups following weaning at about 5 mo.^{Pr83}

Although the prevalence of patent infections of *T. pteropodis* in flying foxes may be high (>50% of *P. poliocephalus* pups), morbidity and mortality are low.⁶ This may be due in part to the low number of mature nematodes (five or fewer) that normally develop. In one report, deaths in two of several

hundred juvenile pups (*P. poliocephalus*) examined were due to aberrant migration of adult worms into the laryngopharynx, producing airway obstruction, in one case and into a bile duct in the other case.⁹ The following is a case report of severe toxocariasis associated with poor weight gain and intestinal volvulus.

CASE REPORT

A 2-mo-old, 92-g female island flying fox (*Pteropus hypomelanus*) was removed from its mother for morphologic measurement and a double-labeled water experiment. The bat was from a private research collection (the LuBee Foundation) of seven megachiropteran species housed in indoor/outdoor enclosures in north-central Florida. All bats were fed a mixture of fruits, vegetables, and a commercial primate diet (Marmoset Chow, Zu/Preem, Hill's Pet Products, Topeka, Kansas 66601, USA). The pup's mother had been imported from Indonesia 1 yr earlier. The bat was underweight for its age. Moderate abdominal distension, thought to be due to feeding, was noted prior to deuterium and oxygen¹⁸ injection (200 μ l s.c.). The pup was returned to its mother after 1 hr and was found on the ground 3 hr later. At 7 hr physical examination showed the pup to be listless and unresponsive, and breathing was labored. She died soon thereafter and was submitted for necropsy.

Significant gross necropsy findings included a 360° counterclockwise twist of the

From the Departments of Small Animal Clinical Sciences (Heard), Comparative Pathology (Garner), and Infectious Diseases (Greiner), College of Veterinary Medicine, University of Florida, Gainesville, Florida 32610, USA. Present address (Garner): Northwest Zoo Path, 15326 Broadway Avenue SE, Snohomish Washington 98290-7042, USA.

Send correspondence to Dr. Darryl Heard, Box 100126 HSC, College of Veterinary Medicine, University of Florida, Gainesville, FL 32610-0216.

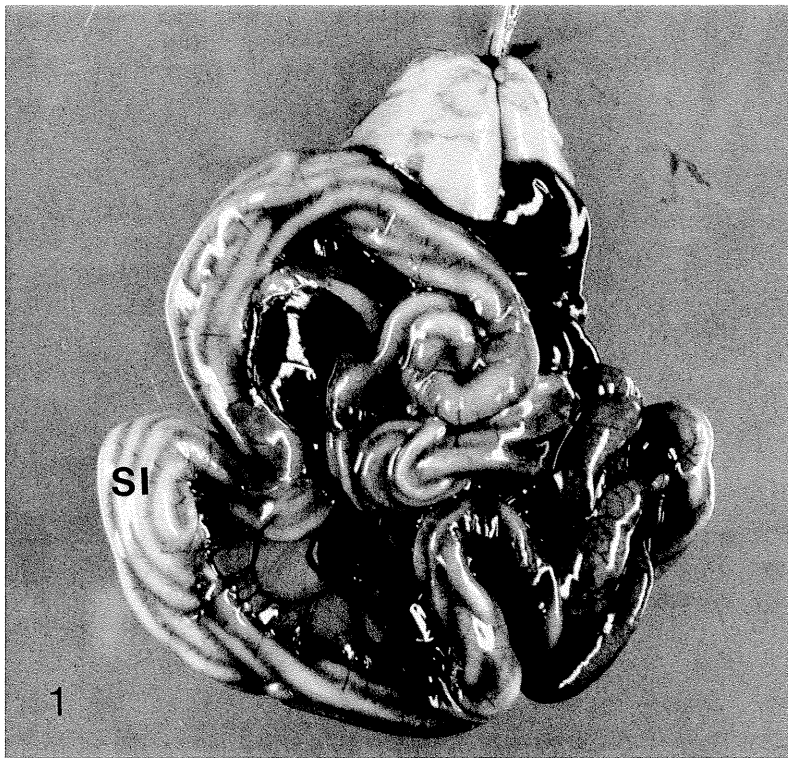


Figure 1. Viscera removed from the body of a suckling island flying fox (*Pteropus hypomelanus*) showing *Toxocara* adults throughout the small intestine (SI).

mesenteric root incorporating the distal half of the jejunum (Fig. 1). The jejunal loop was diffusely reddened, and the mesenteric blood vessels were distended and purple/red. The stomach, duodenum, and anterior half of jejunum were markedly distended with 20 white nematodes (12–14 cm in length, 2 mm in diameter) (Fig. 1). Additionally, a fecal sample from the infected pup contained a large number of *Toxocara* sp. eggs which were approximately 100 μm in diameter (Fig. 2) and covered with irregular pits (Fig. 3). The nematodes were identified as *T. pteropodis* based on the presence of three large lips and body size.^{Ba36} Fecal samples were obtained from all suckling bats in the collection and examined by flotation for endoparasite ova. Eggs were found only in the pup described here. Additionally, milk samples from all lactating bats were examined for nematode larvae, but none were found.

DISCUSSION

This island flying fox probably died from toxemia secondary to small intestinal volvulus. The volvulus was possibly initiated

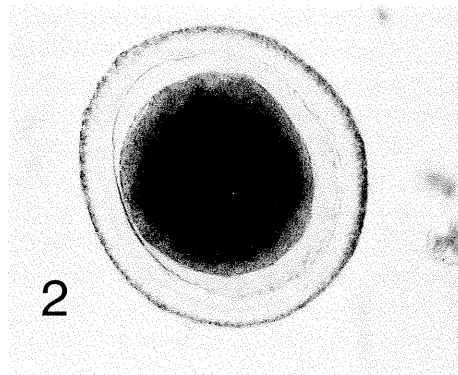


Figure 2. Egg of *Toxocara pteropodis* recovered from the intestinal tract of a suckling island flying fox (*Pteropus hypomelanus*) (egg diameter = 99 μm).

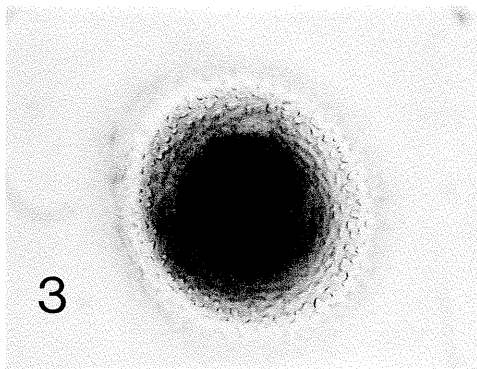


Figure 3. Egg of *Toxocara pteropodis*. Note the egg shell, which shows the irregular shape of the pits in the wall.

by struggling during the injection of deuterium and oxygen¹⁸ and a predisposition to gastrointestinal distension secondary to toxocarasis. The pup's low weight was probably due to the large number of worms interfering with gastrointestinal function by decreasing food absorption and competing for nutrients. Other ascarid species have been reported to cause intestinal obstruction in their definitive hosts (e.g., *Ascaris suum* in pigs).² *Toxocara pteropodis* usually does not kill its host, and there are rarely more than a few worms per host.⁶ The reason for the large number of worms in this pup is unknown.

Toxocara pteropodis was originally postulated as a cause of visceral larva migrans in humans.³ However, it has subsequently been exonerated based on experimental infections in monkeys.⁷ Eradication of *T. pteropodis* in a captive collection of flying foxes is difficult because of the problems in detecting and killing the larval worms in adult bats. At the LuBee Foundation, a control program for this parasite is based on fecal examination for nematode eggs of suckling babies beginning at 2 mo of age. Additionally, pregnant bats are kept in clean cages and are separated from the rest of the colony during parturition and growth of pups. The

pups from these cages are never returned to the breeding colony but are used to form new groups. *Toxocara pteropodis* produce large numbers of eggs, ensuring high environmental contamination.⁸ Unfortunately, ascarid eggs are usually very resistant to most disinfectants and environmental extremes.² Exposure of hosts to large numbers of eggs is reduced by removing food and feces from the environment daily. Piperazine has been reported to be effective for the removal of adult *Toxocara* in other mammal species.² At the LuBee Foundation, ivermectin (200–400 $\mu\text{g}/\text{kg}$ s.c., p.o.) is used, although its efficacy has not been assessed.

Acknowledgment: This article is published as LuBee Foundation Journal Series No. 11.

LITERATURE CITED

1. Baylis, H. A. 1936. A new ascarid from a bat. *Ann. Mag. Nat. Hist. Ser.* 10 17: 360–365.
2. Bowman, D. D. (ed.). 1995. *Georgis' Parasitology for Veterinarians*, 6th ed. W. B. Saunders Co., Philadelphia, Pennsylvania.
3. Moorhouse, D. E. 1982. Toxocarasis. A possible cause of the Palm Island mystery disease. *Med. J. Aust.* 1: 172–173.
4. Prociv, P. 1983. Observations on the transmission and development of *Toxocara pteropodis* (Ascaridoidea: Nematoda) in the Australian grey-headed flying-fox, *Pteropus poliocephalus* (Pteropodidae: Megachiroptera). *Z. Parasitenkd.* 69: 773–781.
5. Prociv, P. 1985. Observations on the prevalence and possible infection source of *Toxocara pteropodis* (Nematoda: Ascaridoidea) in Queensland flying-foxes. *Aust. Mammal.* 8: 319–321.
6. Prociv, P. 1989. Larval migration in oral and parenteral *Toxocara pteropodis* infections and a comparison with *T. canis* dispersal in the flying fox, *Pteropus poliocephalus*. *Intern. J. Parasitol.* 19: 891–896.
7. Prociv, P. 1989. *Toxocara pteropodis* and visceral larva migrans. *Parasitol. Today* 5: 106–109.
8. Prociv, P. 1989. Observations on egg production by *Toxocara pteropodis*. *Int. J. Parasitol.* 19: 441–443.
9. Prociv, P. 1990. Aberrant migration by *Toxocara pteropodis* in flying-foxes—two cases. *J. Wildl. Dis.* 26: 532–534.

Received for publication 20 February 1995.